Abstract # WP114

Dietary exposure of mink (*Mustela vison*) to fish from the upper Hudson River, New York, USA: Organ mass and pathology

Steven J. Bursian[†‡], John Kern[§], Richard E. Remington[§], Jane E. Link[†], Scott D. Fitzgerald[‖ #]

[†] Department of Animal Science, Mich gan State Un versity, East Lans ng, MI 48824, ‡ Center for Integrat ve Tox co ogy, Michigan State University, East Lansing, MI 48824, [§] KERN Statistical Serv ces, 5175 NE River Road, Sauk Rapids, MN 56379,
‖ Department of Pathob o ogy and Diagnostic Investigation, Michigan State University, East Lansing, MI 48824, [#] Diagnostic Center for Population and Animal Health, Mich gan State Un versity, Lansing, MI 48910

The Hudson River is contaminated with polychlorinated biphenyls (PCBs) from Ft. Edward, NY to New York City. The predominant sources of PCBs to the upper Hudson River were 2 General Electric plants in Fort Edward and Hudson Falls, NY that manufactured electrical capacitors containing PCBs beginning in the 1940s. Reports spanning the past 20 years indicated that mink (*Mustela vison*) collected within 1 home range of the upper Hudson River contained concentrations of PCBs in their fat and livers comparable to concentrations causing reproductive impairment in controlled studies with ranch mink, and that tissue concentrations of PCBs have not decreased appreciably[1,2]. Because the mink is a fish-eating mammal that satisfies criteria, including chemical sensitivity, for a sentinel wildlife species, it is a com-monly selected ecological receptor in studies at sites involving aquatic habitats with elevated concen-trations of PCBs[3]. A study was conducted to evaluate the health effects of feeding ranch mink diets containing PCB-contaminated fish from the Hudson River. The effects on adult and offspring organ mass and pathology are reported here. Diets contained 2.5% to 20% Hudson River fish, providing 0.72 to 6.2 µg ∑PCBs/g feed (5.1 to 38 pg toxic equivalents [TEQs]/g feed). Absolute thyroid gland mass was increased in adults, absolute heart mass was decreased in 6-wk-old kits and absolute adrenal gland mass was increased in 31-week-old juveniles exposed to dietary PCBs. The frequency of squamous epithelial proliferation in the mandibles and maxillae of adult mink differed significantly among treatment groups. The percentage of adults with abnormal jaw tissue increased monotonically from that of the control group to that for the 6.1 µg ∑PCBs/g feed group: 0% (0/20; control), 7.1% (1/14; 0.72 µg ∑PCBs/g feed group), 13.3% (2/15; 1.5 µg ∑PCBs/g feed group), 28.6% (4/14; 2.8 µg ∑PCBs/g feed group), 66.7% (12/18; 4.5 µg ∑PCBs/g feed group), 84.2% (16/19; 6.1 µg ∑PCBs/g feed group). There were insufficient numbers of surviving kits and juveniles to assess the incidence of the jaw lesion at 6 and 31 wks of age, respectively. The conclusions and opinions presented here are those of the authors and do not represent the official position of any of the funding agencies, the Hudson River Trustees or the United States.

- PCB contamination of upper Hudson River
  - Major source due to manufacture of electrical capacitors containing PCBs between 1940s to 1977
  - PCBs continue to be detected in fat and liver of mink collected from upper Hudson River at concentrations comparable to those associated with reproductive impairment in controlled studies
  - PCB concentrations have not decreased appreciably over time
- Mink as a sentinel species
  - Fish-eating mammal
  - Exhibits chemical sensitivity to PCBs
  - Top of food chain for aquatic habitat

- To evaluate the health effects of feeding farm-raised mink diets containing PCB-contaminated fish from the Hudson River
  - Effects on adult reproductive performance and offspring growth and mortality through 31 weeks of age (Platform; Wednesday, 4:10 p.m.; # 514)
  - Effects on adult mink and offspring organ mass and pathology

Feed

- Carp collected from Upper Hudson River
  - Contained 36.0 µg ∑PCBs/g wet wt.
- Control fish was ocean herring
  - Contained 0.0854 µg ∑PCBs/g wet wt.
- Fish ground, blended and incorporated into feed

	% of	Targeted dietary concentrations	Analyzed dietary concentrations	Tota TEQs (pg TEQs/g
Hudson River Carp	20%	[illegible]	[illegible]	[illegible]

Animals

- Females
  - n = 15 for control, 4.5 and 6.1 µg ∑PCBs/g feed treatments
  - n = 10 for 0.72, 1.5 and 2.8 µg ∑PCBs/g feed treatments
- Males
  - n = 5/treatment
- Housed singly in open-sided shed

Exposure

- Male mink and females that did not whelp fed their respective experimental diets for 22 wk
- Female mink that whelped fed diets for 23 or 24 wk
- 6 wk-old mink kits exposed in utero through lactation
- Juvenile mink exposed for approximately 31 wk post-parturition

Statistics

- Treatment effects on adult organ masses tested with linear regression models
- Treatment effects on kit/juvenile organ masses tested with linear generalized estimating equations (GEE) regression models to adjust for within-litter correlation
- EC20s and EC50s for jaw lesions in adults estimated by logistic regression

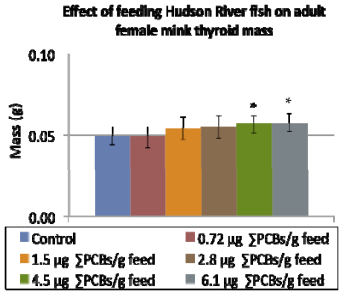

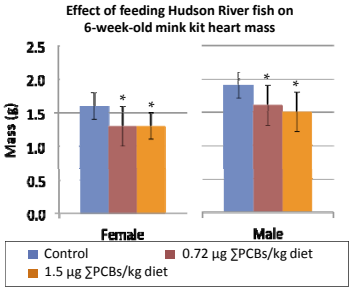

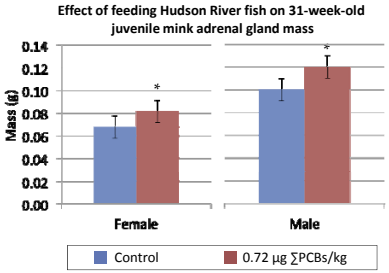

Effective concentrations of ∑PCBs and TEQs in feed and liver producing jaw lesions in 20% and 50% of adult mink (EC20, EC50)

		EC20	95% Confidence Interval	EC50	95% Confidence Interval
Feed	µg ∑PCBs/g feed	2.3	1.5 3.1	3.9	3.2 4.6
	pg TEQs/g feed	15	10 20	25	21 29
Liver	µg ∑PCBs/g liver	2.8	2.1 3.6	4.4	3.7 5.1
	pg TEQs/g liver	89	58 121	151	125 178

Photomicrographs showing severity of jaw lesions

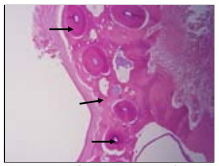

Normal maxilla from a control adult female mink showing teeth (**T**) and peridontal ligament (**PL**)

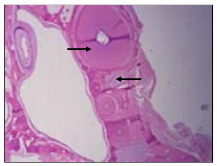

Maxilla of a 4.5 µg ∑PCBs/g feed adult female mink showing mild squamous epithelial cell (**SCC** – squamous cell cyst) proliferation (one

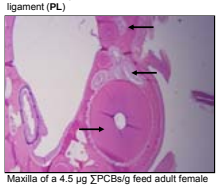

Maxilla of a 4.5 µg ∑PCBs/g feed adult female mink showing moderate squamous epithelial cell proliferation at two sites

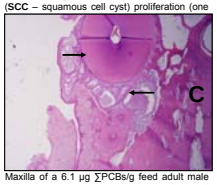

Maxilla of a 6.1 µg ∑PCBs/g feed adult male showing severe squamous epithelial cell proliferation shown at multiple sites

- Consumption of feed containing fish from the upper Hudson River resulted in:
  - ↑ thyroid mass of adult females, ↓ heart mass of 6-wk-old kits, ↑adrenal gland mass of juvenile mink
  - Development of a jaw lesion in adult mink characterized as mandibular and maxillary squamous epithelial proliferation
    - Dietary EC50 = 3.9 µg ∑PCBs/g feed (25 pg TEQs/g feed); dietary EC20 = 2.3 µg ∑PCBs/g feed (15 pg TEQs/g feed)
    - Hepatic EC50 = 4.4 µg ∑PCBs/g liver (151 pg TEQs/g liver); hepatic EC20 = 2.8 µg ∑PCBs/g liver (89 pg TEQs/g liver)
- Jaw lesion EC20 is 6-fold greater than LC20 based on kit survivability and EC50 is 1.7-fold greater than LC50

[1]Foley RE, Jackling SJ, Sloan RL, Brown MK. 1988. Organochlorine and mercury residues in wild mink and otter: Comparison with fish. Environ Toxicol Chem 7:363-374.

[2]Mayack DT, Loukmas J. 2001. Progress report on Hudson River mammals: Polychlorinated biphenyl (PCB) levels in mink, otter, and muskrat and trapping results for mink, the Upper Hudson River drainage, 1998-2000. Progress Report. New York Department of Environmental Conservation. Albany, NY, USA.

[3]Basu N, Scheuhammer AM, Bursian SJ, Rouvinen-Watt K, Elliott J, Chan HM. 2007. Mink as a sentinel species in environmental health. Environ Res 103:130-144.